Extraskeletal Pelvic Ewing Sarcoma: an intraoperative diagnostic challenge for the Gynaecological Pathologist

[1]Cheng H, [3]Devaraj M, Blake D[2], [4]Watts K, [4]Cuthbert G, [1]Slana B, [2]Korompelis P, [1]Ralte A
[1]South of Tyne and Wear Pathology, Queen Elizabeth Hospital, Gateshead
[2]Northern Gynaecological Oncology Centre, Queen Elizabeth Hospital, Gateshead
[3]Cellular Pathology, James Cook University Hospital, Middlesbrough
[4]North East and Yorkshire Genomic Laboratory Hub, Newcastle-upon-Tyne

Introduction

- Extraskeletal Ewing Sarcoma (EES) is a malignant small round blue cell tumour (SRBCT) that belongs to the Ewing sarcoma family of tumours (ESFT)
- It was first described in 1969 but remains an elusive disease with few reports in literature. Worldwide incidence is 0.4 per million population
- It shows a bimodal age distribution with peak incidence <5yrs and >35yrs
- It shows no sex or race predilection unlike Ewing sarcoma of bone (ESB)
- We present a rare case of EES arising in the pelvic soft tissues of a postmenopausal woman which was submitted for frozen section with clinical and radiological diagnosis of an ovarian tumour

Clinical History

- 50 years old postmenopausal lady (CA125=46) underwent laparotomy for an ovarian mass with a view to proceed with primary debulking if gynaecological malignancy confirmed on frozen section
- Laparotomy revealed friable haemorrhagic mass in the rectovaginal pouch adherent to the rectal wall, urinary bladder and right fallopian tube. Mullerian structures visible and grossly normal
- A tissue biopsy of the mass was submitted for frozen section diagnosis

Intraoperative Cytology

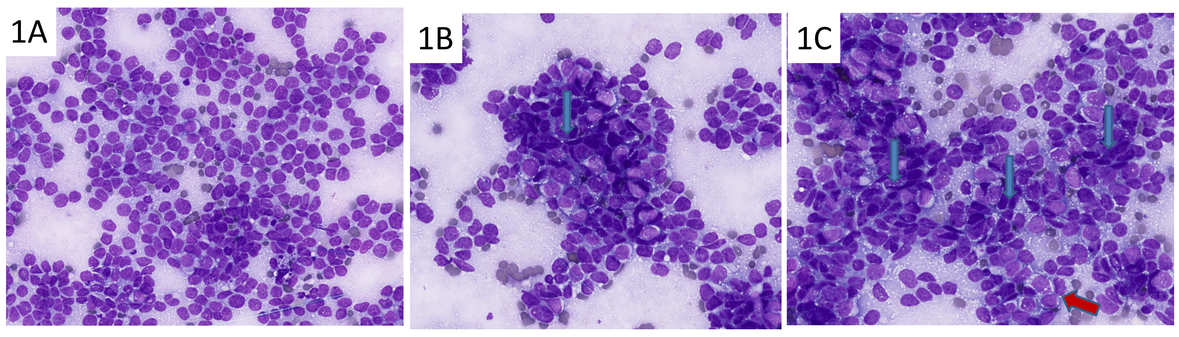

Airdried smears stained with DiffQuik showing:-

- Loosely cohesive and dispersed (1A) round to oval cells with scanty, occasionally vacuolated cytoplasm and a tigroid background (red arrow)
- Smooth or slightly folded nuclear outlines with fine, uniform chromatin and small nucleoli
- Typical 'light' and 'dark 'cells (blue arrow)
- Hint of nuclear moulding
- Nuclear streaking artefacts and lymphoglandular bodies not seen on four slides prepared for cytological examination

Frozen Section Histology

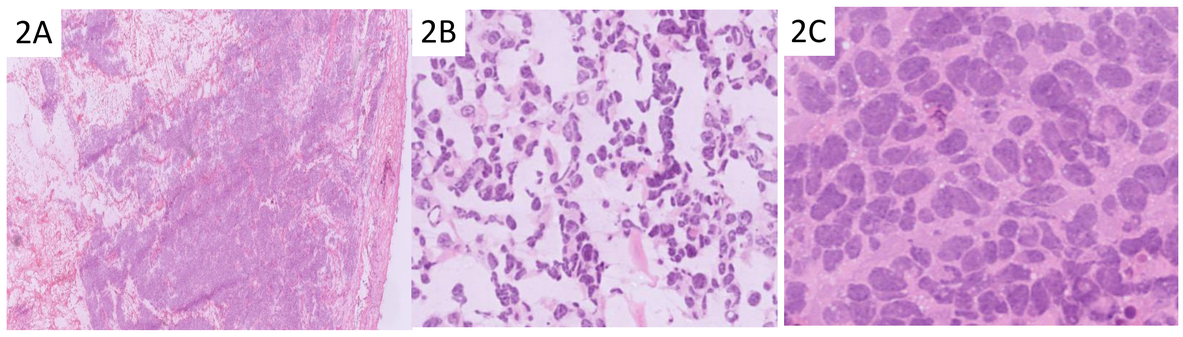

- Solid sheets of a poorly differentiated malignant tumour with areas of necrosis (2A) and focal filigree pattern (2B)
- Cytoplasm is indistinct, nuclei show moulding and hyperchromasia but nuclear details unclear (2C)
- *Frozen section diagnosis:* malignant small round blue cell tumour
- Definitive diagnosis deferred to paraffin
- Patient underwent total hysterectomy and bilateral salpingo-oophorectomy
- Tumour stuck to but separable from Mullerian structures, but unresectable without extensive surgery involving bowel and bladder so left in-situ pending final histology

Permanent Sections

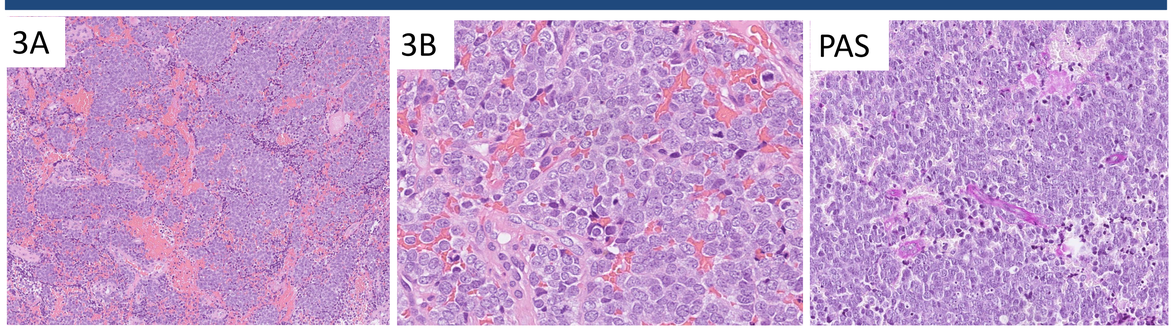

- Syncytial, patternless sheets of a densely cellular haemorrhagic tumour (3A,HE, low power)
- Uniform cells with scanty to moderate pale cytoplasm, round to oval 'smoky' nuclei with fine chromatin, distinct nuclear membranes, small nucleoli and low mitotic activity. Note the 'light' and 'dark' cells (3B, HE, high power)
- PAS shows no evidence of cytoplasmic glycogen
- Mullerian structures within normal limits

Immunohistochemistry (IHC)

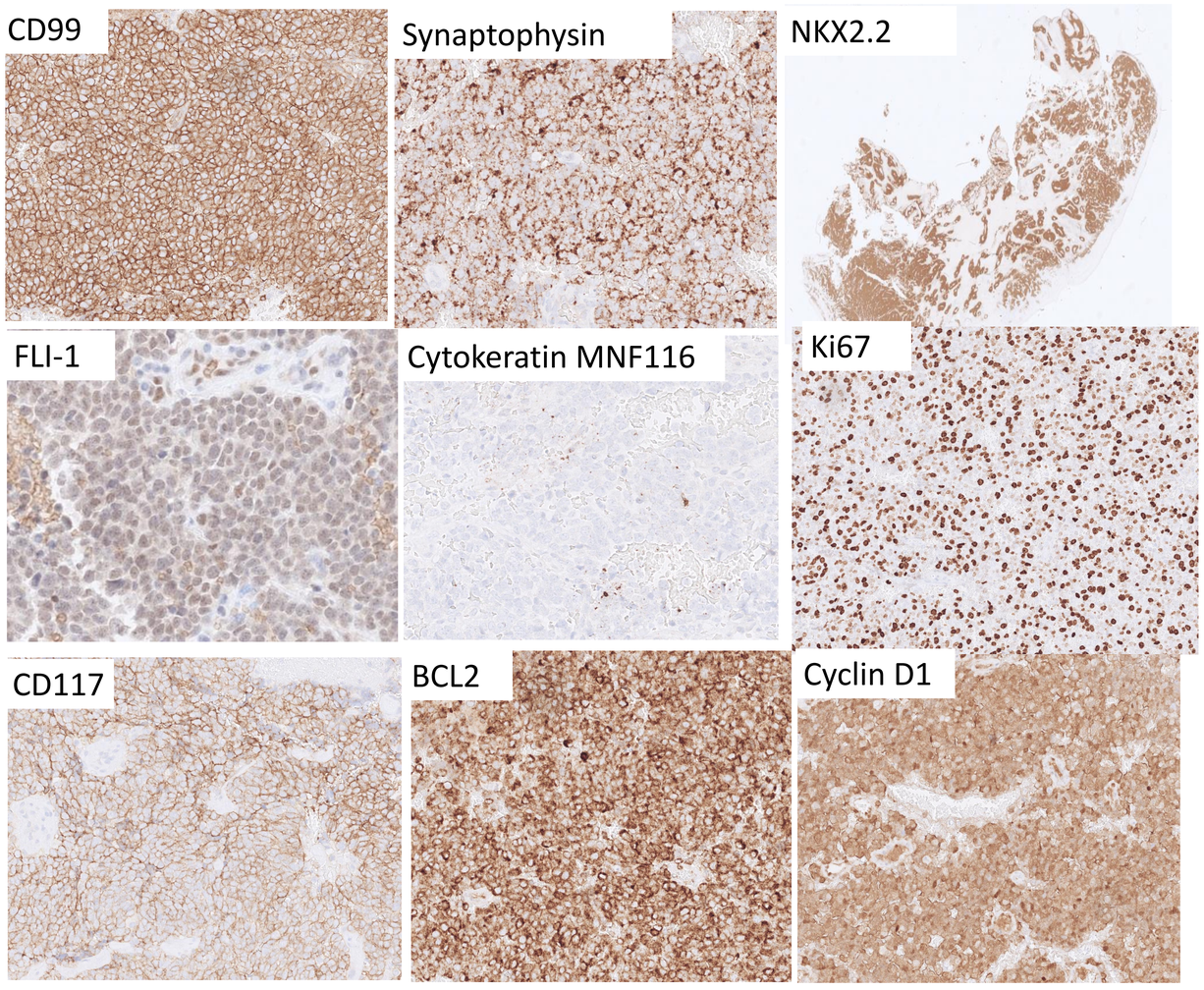

Summary of Immunohistochemistry

Positive: CD99,synaptophysin,NKX2.2, FLI1 (weak, nuclear), CD117,BCL2,vimentin
Negative:CKC (granular, occasional cells),CD56,chromogranin, ERG, CD10, DOG1,LCA,S100,SOX10, HMB45,Cyclin D1(cytoplasmic),PAX8,ER,PR,WT1,p53wt

Interphase FISH

- EWSR1 REARRANGED signal pattern in 94 of the 100 nuclei examined
- EWSR1:FLI1 fusion POSITIVE signal pattern in 90 of 100 nuclei scored, indicating a clone with translocation t(11;22)(q24;q12)
- Features consistent with Ewing Sarcoma

Final Diagnosis

Biopsy, pelvic mass: Extraskeletal Ewing Sarcoma, most likely arising from soft tissues of pelvis

Discussion

- EES of soft tissues can occur in any anatomic region, but the most common sites are the upper thigh, buttocks, upper arm and rarely the pelvis and peritoneum
- Clinical features are nonspecific and dependent on site of origin
- Radiological features are also non specific and if located in the pelvis, may be mistaken primary gynaecological tumour, generating a frozen section request by the Gynae-oncology Team
- Clear communication between surgeon and pathologist is essential at frozen section, as nuclear details can be fuzzy on frozen section and if intraoperative findings are not conveyed to the pathologist, this tumour may be misdiagnosed as a poorly differentiated malignant tumour of primary gynaecological origin with significant clinical and prognostic differences
- Intraoperative cytology is useful as it shows the appearance of a small round blue cell tumour (SRBCT); features that differentiate from other SRBCTs is the absence of lymphoglandular bodies and lack nuclear streaking artefacts
- Even on permanent sections and a complete panel of IHC there are diagnostic challenges due to overlap in the morphology and immunoprofile with other SRBCTs
- Morphology and IHC is sufficient in some but not all cases (Small Cell Neuroendocrine Carcinoma/ SCNEC may show membrane positivity for CD99. FLI1 is also positive in lymphoblastic lymphoma. NKX2.2 is sensitive but not very specific, and is commonly positive in SCNEC. Synaptophysin positivity is usually focal in EES but can be strong and diffuse as was seen in our case. EES and SCNEC both express CD117,BCL2). Molecular genetic studies are required to confirm the diagnosis in equivocal cases
- Features to prompt the pathologist to perform molecular genetics are:
  - Absence of lymphoglandular bodies and nuclear streaking artefact with presence of light and dark cells on cytology
  - Smoky 'almost bland' nuclei with fine chromatin, small nucleoli and distinct nuclear membranes
  - Areas of necrosis but low mitotic activity
  - Strong membrane staining for CD99, NKX2.2+,CKC-, Ki67 lower than expected for SCNEC
- Gynaecological pathologists need to be aware of this entity as it can occur in the pelvis of older women mimicking an ovarian tumour and may also disseminate within the peritoneal cavity in a pattern similar to that of primary tubo-ovarian cancer
- Poor prognostic factors are older age and pelvic location
- Current treatment recommendation by the NCCN (National Comprehensive Cancer Network) is wide surgical resection and/or radiotherapy plus chemotherapy

All authors confirm that this is work is not affiliated with any commercial sponsor or external organisation that could affect independence or objectivity.
Acknowledgement: Dr James Sampson for his review at the Sarcoma MDT

REFERENCES
El Weshi et al. Extraskeletal Ewing's Sarcoma family of tumours in adults: Analysis of 57 patients form a single institution Clin Oncol22:374-381.2010
Applebaum et al. Clinical features and outcomes of patients with Extraskeletal Ewing Sarcoma. Caner 17:3027-3032,2011
Abboud et al. Extraskeletal Ewing sarcoma: Diagnosis, management and prognosis (Review) Oncology Letters 2021:21(5)354